

흉골하 갑상선종의 수술적 치료

최종욱¹ · 김영호¹ · 이재용¹ · 김용환¹ · 성태현² · 유홍균²

Surgical Management of Substernal Goiter

Jong Ouck Choi, MD¹, Young Ho Kim, MD¹, Jae Young Lee, MD¹,
Yong Hoan Kim, MD¹, Tae Hyun Sung, MD² and Hong Kyun Yoo, MD²

¹Department of Otorhinolaryngology-Head and Neck Surgery, College of Medicine, Korea University, Seoul,

²Department of Otolaryngology, Sun General Hospital, Taejeon, Korea

ABSTRACT

Background and Objectives : Substernal goiter, defined as any thyroid enlargement that has greater mass inferior to the thoracic inlet, is a relatively rare disease with a potential for malignancy and the risk of postoperative airway obstruction secondary to tracheomalacia. We investigated clinical characteristics of substernal goiters and analyzed the results of the treatment to establish modalities of the surgical management. **Materials and Methods** : We examined, retrospectively, ten cases of substernal goiters and reviewed their clinical features, radiological findings, histopathologic findings, operative findings and postoperative complications. **Results** : We found tracheal deviations in six patients, tracheomalacia in three patients and calcification in two patients. We performed partial thyroidectomy for 9 cases and total thyroidectomy and superior mediastinal dissection were done for a case which revealed to be follicular carcinoma. The main histopathologic findings were multinodular goiter in five cases, followed by follicular adenoma, and follicular carcinoma in one case. Endotracheal intubation was removed after 24 hours postoperatively for six cases who showed severe tracheal compression and tracheal deviation and the tracheopexy (tracheal suspension) to the sternum was performed for one case among them. **Conclusion** : Because of the possibilities of malignancy and the acute airway obstruction, the surgical treatment and careful postoperative airway management should be emphasized for substernal goiter. (**Korean J Otolaryngol 1998;41 (7):935-939**)

KEY WORDS : Substernal goiter · Tracheopexy · Airway management.

가
가³⁾
(tracheomalacia)
(tracheo-
1)
pexy) 가⁴⁾⁵⁾
가 10
가²⁾

: 1998 2 18 / : 1998 5 14
: , 136 - 705 5 126 - 1

: (02) 920 - 5761 · : (02) 925 - 5233

E - mail : KUENT@nuri.net

1991 9 1997 9

12
2 10
1 : 2.3 가
56.7

방사선학적 검사

(Figs. 1 and 2).

수술적 접근방법

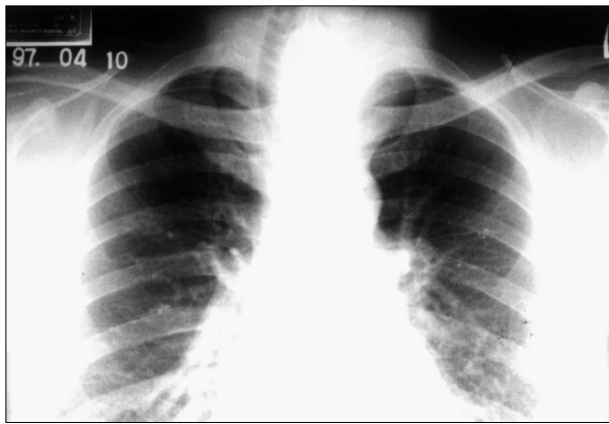


Fig. 1. Posteroanterior chest view showing a deviated trachea.

가
(finger tip)
(unilat-
(subtotal thy-
roidectomy)
1
(superior
mediastinal dissection)

(Fig. 3).

술후 합병증

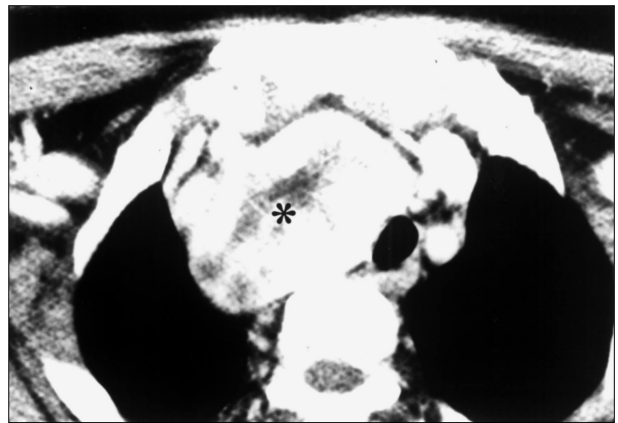


Fig. 2. Computerized tomographic scan showing an inhomogeneous substernal mass.

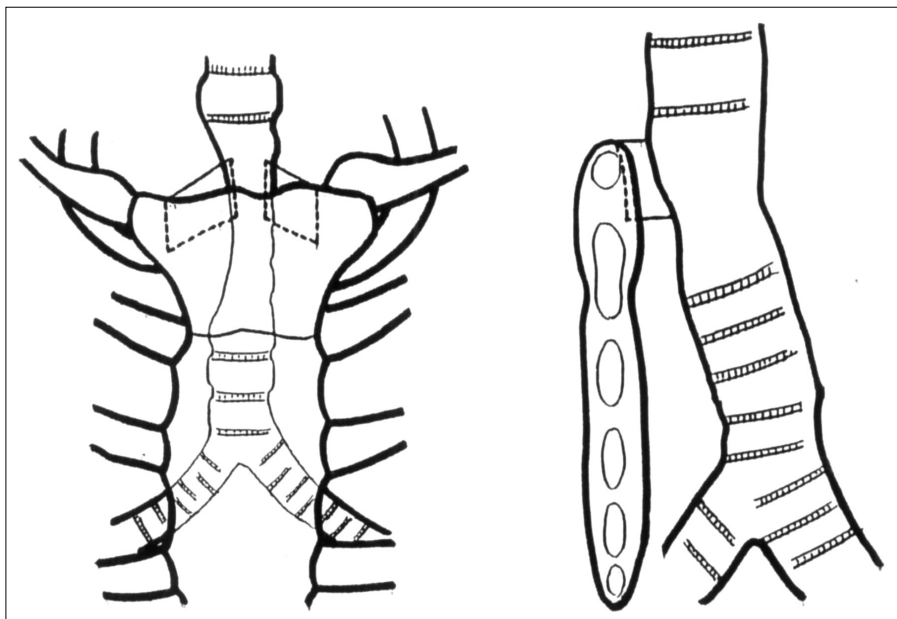


Fig. 3. Diagram of tracheopexy to sternum.

가 6, 4. 6, 3, 2 (Table 1).

술전후 폐기능검사

FEV1/FVC FEV1/FVC가 70% 5, 4, 1 (Table 1). 70% 9, 1

3 (Table 2).

6 가, 4 (Table 1).

Table 1. Case summaries (clinical manifestations, radiologic and pathologic findings)

No. of cases (age / sex)	Cervical mass	Hoarseness	Dysphagia	Radiology	Pathologic finding
Normal respiration group					
Case 1 (F/68)	+	-	-	TD*	Multinodular goiter
Case 2 (F/45)	-	-	-	-	Multinodular goiter
Case 3 (M/75)	+	-	-	TD, TC [†] , CA [‡]	Multinodular goiter
Case 4 (F/48)	+	-	-	-	Multinodular goiter
Case 5 (M/77)	-	-	-	TD	Multinodular goiter
Case 6 (F/51)	+	+	-	TD, TC	Follicular adenoma
Abnormal respiration group					
Case 7 (F/52)	+	-	-	-	Follicular adenoma
Case 8 (M/42)	+	-	-	TD, TC	Follicular adenoma
Case 9 (F/43)	-	+	-	CA	Follicular adenoma
Case 10 (F/66)	-	+	+	TD	Follicular adenoma

TD* : tracheal deviation, TC[†] : tracheomalacia, CA[‡] : calcification

Table 2. Treatment results

No. of cases	Approach	Operation	Tracheopexy	Complication	PFT (FEV1/FVC, %)	
					Preop	Preop
Normal respiration group						
Case 1	Transcervical	ST*	-	-	78	79
Case 2	Transcervical	ST	-	-	84	84
Case 3	Transcervical	ST	-	-	73	76
Case 4	Transcervical	ST	-	-	83	83
Case 5	Transcervical	ST	-	-	72	75
Case 6	Transcervical	UT [†]	-	-	86	86
Abnormal respiration group						
Case 7	Transcervical	UT	-	-	65	75
Case 8	Transcervical	UT	+	-	64	74
Case 9	Transsternal	TT [‡]	+	Hematoma	61	73
Case 10	Transcervical	ST	+	Hematoma	63	68

ST* : subtotal thyroidectomy, UT[†] : unilateral thyroidectomy, TT[‡] : total thyroidectomy

10
6 , 4 ,
5 , 4 ,
1 . 9
가 가 , 1
3
가
:

REFERENCES

- 1) Katlic MR, Wang C, Grillo HC. *Substernal goiter. Ann Thorac Surg* 1985;39:391-9.
- 2) Johnston JH, Twente GE. *Surgical approach to intrathoracic (mediastinal) goiter. Ann Surg* 1956;143:572.
- 3) Wada H, Teramatsu T. *Mediastinal tumors: A statistical nationwide report of 1,546 cases between July, 1975 and May, 1979 in Japan. JJATS* 1981;30:334-8.
- 4) Alfonso A, Christoudias G, Amaruddin Q, Herbsman H, Gardner B. *Tracheal or esophageal compression due to benign thyroid disease. Am J Surg* 1981;142:350-4.
- 5) Dinstl K, Keminger K. *Zur operativen therapie der Tracheomalacie. Acta Chir Austriaca* 1970;3:100.
- 6) Katlic MR, Grillo HC, Wang C. *Substernal goiter: Analysis of 80 patients from massachusetts general hospital. Am J Surg* 1985;149:283-7.
- 7) Newman E, Shaha AR. *Substernal goiter. J Surg Oncol* 1995;60:207-12.
- 8) Fui SNT, Prior J, Saunders AJ, Maisey MN. *Posterior intrathoracic goitre as a cause of thyrotoxicosis. Br J Radiol* 1979;52: 995-7.
- 9) Lawson W, Reino AJ, Biller HF. *Management of substernal thyroid disease. In: Thyroid disease: Endocrinology, surgery, nuclear medicine and radiltherapy. 2nd ed. Philadelphia: Lippincott-Raven Publishers;1997. p.447-56.*
- 10) Allo MD, Thompson NW. *Rationale for the operative management of substernal goiters. Surgery* 1983;94:969-77.
- 11) Geelhoed GW. *Tracheomalacia from compressing goiter: Management after thyroidectomy. Surgery* 1988;104:1100-8.
- 12) Singh B, Lucente FE, Shaha AR. *Substernal goiter: A clinical review. AJR* 1994;15:409-16.