Head and Neck

Korean J Otorhinolaryngol-Head Neck Surg 2026;69(11):533-41 / eISSN 2092-6529

https://doi.org/10.3342/kjorl-hns.2026.00661

Differentiation of Diplophonia Using Vibration Simulator

Jin Choon Lee[1], Soo-Geun Wang[1], In-Ho Bae[2,3], Jaewon Kim[3], Eui-Suk Sung[1], Minhyung Lee[3], Sung-Chan Shin[1], Yong-Il Cheon[4], Ha-Nee Kwon[4], Soon-Bok Kwon[2,5], and Jung Hoon Ro[6]

[1]*Department of Otorhinolaryngology-Head and Neck Surgery, School of Medicine, Pusan National University, Yangsan; and*
[2]*Interdisciplinary Program for Cognitive Science, Pusan National University, Busan; and*
[3]*Department of Otorhinolaryngology-Head and Neck Surgery, Pusan National University Yangsan Hospital, Yangsan; and*
[4]*Department of Otorhinolaryngology-Head and Neck Surgery, Pusan National University Hospital, Busan; and*
[5]*Department of Humanities, Language and Information, Pusan National University, Busan; and*
[6]*Department of Biomedical Engineering, School of Medicine, Pusan National University, Yangsan, Korea*

진동 시뮬레이터를 이용한 이중음성의 감별

이진춘[1] · 왕수건[1] · 배인호[2,3] · 김재원[3] · 성의숙[1] · 이민형[3] · 신성찬[1] · 천용일[4] · 권하늬[4] · 권순복[2,5] · 노정훈[6]

[1]부산대학교 의과대학 이비인후과학교실, [2]부산대학교 인지과학전공, [3]양산부산대학교병원 이비인후과, [4]부산대학교병원 이비인후과, [5]부산대학교 언어정보학과, [6]부산대학교 의과대학 의공학교실

Background and Objectives This study evaluated the efficacy of a silicon vibration simulator (VS) by determining whether it could convert the acoustic energy of voice into vibration. We also compared the accuracy of digital kymography (DKG), two-dimensional digital kymography (2D DKG), acoustic voice analysis, and auditory perception for differentiating diplophonia and examined the differences between DKG and 2D DKG in this task.

Subjects and Method One normophonic male and one vocally healthy male who can produce diplophonia participated for the verification of efficacy of a silicon VS. Twenty-nine diplophonic voice samples and 41 non-periodic voice samples were enrolled in this study. Auditory and visual perceptual judgement about DKG, 2D DKG, and the sound waveform were performed. DKG and 2D DKG images of the VS were captured by a high-speed digital camera in the multi-functional examination system.

Results The simulator achieved exact conversion of voice-derived acoustic energy into vibration. Compared with acoustic voice analysis and auditory perceptual judgement, DKG using the VS showed the highest diagnostic validity for differentiating diplophonia as follows: 0.9655 for sensitivity; 0.9756 for specificity; 0.9714 for accuracy; the positive likelihood ratio of 39.5862 and the negative likelihood ratio of 0.0353. For 26 of the 29 diplophonic samples, differentiation was easier with 2D DKG than with DKG.

Conclusion The silicon VS reproduced vibration patterns resembling those of human vocal folds and effectively differentiated diplophonia. Although 2D DKG generally provided more intuitive visualization, the conventional DKG was more useful for diplophonic voices containing long metacycle components.

Korean J Otorhinolaryngol-Head Neck Surg 2026;69(11):533-41

Keywords Digital kymography; Diplophonia; Silicon vibration simulator; 2D DKG.

Received August 22, 2026
Revised August 25, 2026
Accepted August 27, 2026

Address for correspondence
Jung Hoon Ro, PhD
Department of Biomedical Engineering, School of Medicine, Pusan National University, 49 Busan University Road, Mulgeum-eup, Yangsan 50612, Korea
Tel +82-51-240-7933
E-mail jhro@pnu.edu

This is an Open Access article distributed under the terms of the Creative Commons Attribution Non-Commercial License (https://creativecommons.org/licenses/by-nc/4.0) which permits unrestricted non-commercial use, distribution, and reproduction in any medium, provided the original work is properly cited.

Introduction

Methods for evaluating vocal cord vibration can be classified according to how the data are obtained. Indirect, noninvasive approaches use voice signals, electroglottography (EGG),[1] or photoglottogram[2] and allow vibratory patterns to be examined without causing patient discomfort; however, locating a diplophonic segment can be cumbersome and may require sustained attention. Direct endoscopic approaches include high-speed videoendoscopy (HSV), laryngeal videostroboscopy, videokymography (VKG), and two-dimensional videokymography (2D VKG).[3] HSV playback recordings can additionally be analyzed using glottal area waveforms (GAW), glottal width waveforms,[4] kymographic edge displays,[5] digital kymography (DKG),[6] and two-dimensional digital kymography (2D DKG).[7] Together, these methods can be used effectively to evaluate vocal-cord vibration.

Many methods have been developed to evaluate vocal cord vibration using vibration simulators (VS) such as artificial vocal cord replicas,[8] excised larynges,[3] and computational models.[9] The advantages of these methods are that they are easy to reduplicate and are not influenced by the external environment. Most artificial vocal cord replicas were airflow-driven types.[8,10,11] There have been few studies on oscillating simulators that use the acoustic energy of the voice.

The authors previously developed the silicon VS, which converts the acoustic energy of the voice to vibration, and used the silicon VS to verify the effectiveness of differentiating diplophonic voice using a high-speed digital camera (USC-700 MF, U-medical) and multi-functional examination system.[7]

This study addressed three questions. First, can the silicon VS effectively convert the acoustic energy of the voice into vibration? Second, which of DKG, 2D DKG, acoustic voice analysis, and auditory perception is most accurate in differentiating diplophonia? Third, how do DKG and 2D DKG differ in their ability to differentiate diplophonia?

Subjects and Methods

Subjects

Participants

A 35-year-old normophonic male and a 65-year-old normophonic male who can produce diplophonia participated for verification of VS.

Voice sample

Seventy voice samples diagnosed with laryngeal diseases (unilateral vocal cord palsy, glottic cancer, and vocal polyp) by otolaryngologist were used: diplophonic voice samples (n=29, mean age 56.9±13.37 years) and non-periodic voice samples (n=41, mean age 58.2±12.99 years). The diplophonic voice samples consisted of 23 voices from UVCP patients, 1 voice from glottic cancer patients, and 5 voices from vocal cord polyp patients, and the non-periodic voice samples consisted of 20 voices from UVCP patients, 15 voices from glottic cancer patients, and 6 voices from vocal cord polyp patients.

All the voice samples were digitalized at a 44100 Hz sampling rate, 16-bit quantization using CSL 4500 (KayPENTAX). For confirmation a diplophonic voice sample, one ENT doctor and one speech-language pathologist were engaged. First, voice samples presenting perceptually two pitches at auditory perceptual assessment, quasi-periodic perturbation and subharmonics at acoustic analysis, and three consecutive quasi-periodic variation at DKG were selected in pathologic voice samples. And, these samples verified as the diplophonia were reconfirmed again through HSV playback. Intra-rater reliability show statistical significance with a high level of agreement (kappa=0.983), and both diplophonic and non-periodic voice samples evaluated equally by two raters were used for this study. This study was approved by the Institutional Review Board of Pusan National University Hospital (IRB No. 51-2026-090).

Materials

Specification of VS

Voice was supplied to the VS from a Galaxy S6 smartphone (Samsung) through an MQ-L420 amplifier (Samsung), and two sets of woofer speakers converted the acoustic energy into vibration. The amplifier had a rated output of 55 W. The woofer specifications were a maximum output of 100 W, an impedance of 8 Ω, an aluminum frame, and a 13-oz magnet. Two pairs of left and right metal rods were connected to both woofer speakers, and vibration was transmitted through the rods. An acrylic plate was fixed at the center of the rods, and the silicon model was placed on the plate (Fig. 1). To reproduce an appropriate vocal-cord vibratory pattern, the model was designed with a hardness similar to that of the vocal cord and with an edge made as thin as possible.



Fig. 1. Schematic illustration of VS system. A: Sound generator (smartphone). B: Amplifier. C: VS using silicon block. D: High-speed videocamera. E: Computer. F: Magnifying view of silicon block (coronal section). VS, vibration simulator.

Camera system

B/W global shutter type Complementary Metal-Oxide-Semiconductor (CMOS) image sensor high-speed digital videocamera (USC-700MF, U-medical) for DKG and 2D DKG was used. A rigid endoscope (Storz, 10 mm, 0° Laryngoscope) connected with videocamera using zoom coupler of 16−34 mm (MGB) was used. 300 W Xenon light source (NOVA 300, Storz) was used for illumination. For analysis of DKG and 2D DKG, multi-functional examination system was used, and the resolution of the 2D DKG images was 240×320 pixels (1350 FPS).

Methods

Verification of VS using DKG and 2D DKG

The verification proceeded in two recording stages. First, a high-speed digital camera captured vocal-cord vibration in both normophonic males while PCquirer (Scicon R&D Inc.) recorded their voice and EGG signals. The recorded voice was then delivered to the amplifier, and a high-speed digital camera captured the resulting vibration of the silicon model. DKG and 2D DKG were generated with the multi-functional examination system. Their validity with the VS was assessed by comparing the sound waveform and EGG with the vibration patterns of the human vocal cord and the VS. For the comparison between imaging methods, DKG and 2D DKG were obtained from the same domain of the HSV playback, after which the DKG image was compared with the vibratory pattern in the sequential 2D DKG images.

Raters

The raters consisted of one ENT doctor and three speech-language pathologists who specialized in the voice disorders. They had experience (mean 16.8 years, range 7−40 years) in the field of dysphonia assessment and treatment. Diplophonia is defined as showing quasi-periodic patterns in the harmonics of the acoustic analysis of speech signals, EGG, DKG, and acoustic spectrogram.

Auditory perceptual judgement for diplophonia

The auditory perceptual judgement of voice samples were implemented by four voice specialists. The positive was defined as simultaneous auditory perception of two pitches during voicing and sample showing agreement of 75% or more were selected.[12]

Visual perceptual judgement for presence of quasi-periodic perturbation in voice signal

For acoustic analysis of quasi-periodic perturbation finding, we used Praat 6.0.16.[13] Sound waveform was evaluated

visually by four voice specialist. If raters could find three consecutive same images (quasi-periodic perturbation), in sound analysis, those were defined as positive and those samples showing agreement of 75% or more were selected. The quasi-periodic perturbation of diplophonia was defined similar to Hong and Kim.[14]

Visual perceptual judgement for presence of quasi-periodic variation in DKG and 2D DKG

For DKG and 2D DKG assessment of quasi-periodic variation finding, we input the voice samples into VS, and then captured the vibration using HSV camera. To obtain DKG and 2D DKG from HSV, multi-functional examination system was used. DKG and 2D DKG were evaluated visually by four voice specialist. If raters could find three consecutive same images (quasi-periodic variation) in DKG, those were defined as positive and those samples showing agreement of 75% or more were selected.[1,4] Also, we evaluated easiness of differentiation between DKG and 2D DKG.

Statistical analysis

Intra-rater reliability for voice sample selection was assessed using the kappa statistic. The reliability measures used in the analysis of the present voice sample were intraclass correlation coefficient (ICC) for inter- and intra-reliability. Inter-rater reliability was analyzed using the entire sample, and to examine intra-rater reliability, repeated testing was conducted with a random voice sample of 20. For identify validity of evaluation, we calculated for sensitivity, specificity, accuracy, positive likelihood ratio (LR+), and negative likelihood ratio (LR-) with 95% confidence intervals.

Results

Verification of VS

DKG analysis of HSV playback showed corresponding vibration patterns in the human vocal cord and the VS. In the vocally healthy male, both patterns repeated at the same frequency within the same time domain (Fig. 2). In the normophonic male who could produce diplophonia, human-vocal-cord DKG showed regular false-vocal-cord contact once for every two true-vocal-cord contacts (Fig. 3A-2 and A-3), whereas VS DKG clearly showed three cycles per metacycle, representing triplophonia (Fig. 3B-2 and B-3).

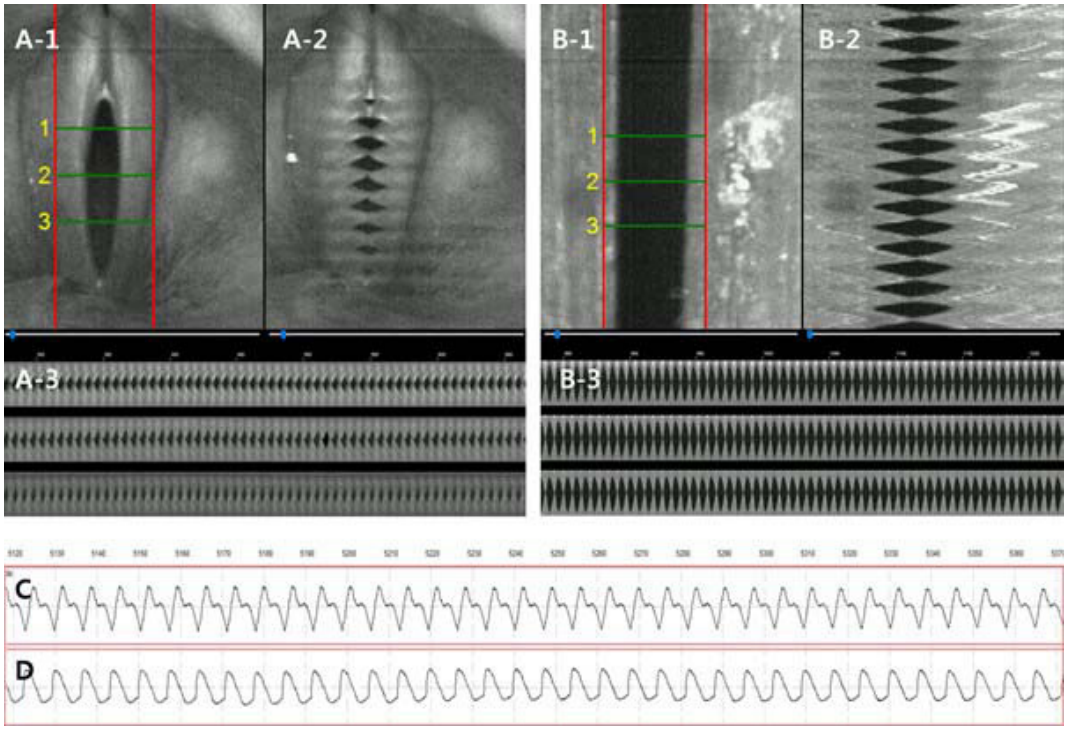

Fig. 2. Images from HSV, 2D DKG, DKG, sound waveform, electroglottography in 35-year-old vocally healthy male. A-1: HSV image from human vocal cord. A-2: 2D DKG image from human vocal cord. A-3: DKG image from human vocal cord. B-1: HSV image from VS. B-2: 2D DKG image from VS. B-3: DKG image from VS. In vocally healthy male, the images of DKG represented similarly on both human vocal cord and VS (A-3 and B-3). (C) and (D) revealed same vibration frequency correspond to (B-2) and (B-3). HSV, high-speed videocamera; 2D DKG, two-dimensional digital kymography; DKG, digital kymogram; VS, vibration simulator.

Supplementary Video 1 shows vocal cord vibration in normophonic male who produce diplophonia. Supplementary Video 2 shows HSV image from vibration simulator in diplophonic case.

Auditory perceptual judgement for diplophonia

As a result of differentiating diplophonia using auditory perceptual judgement, it showed that sensitivity, specificity, accuracy, LR+, and LR- was 0.9655, 0.9024, 0.9286, 9.8966,

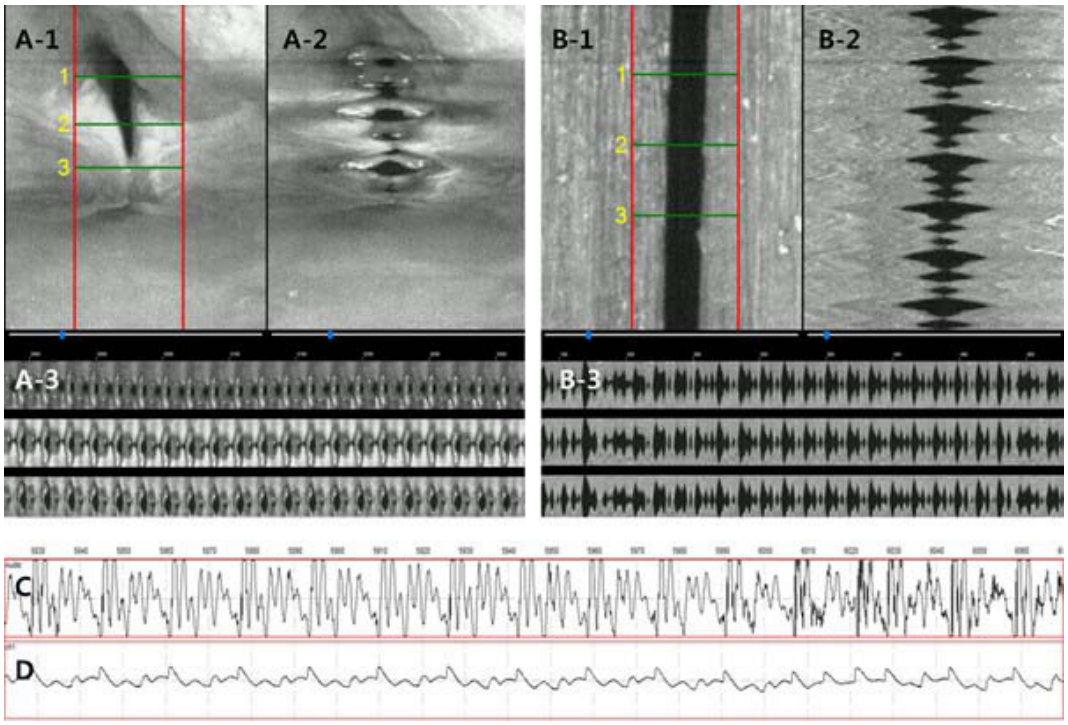

Fig. 3. Images from HSV, 2D DKG, DKG, sound waveform, electroglottograph in 65-year-old normophonic male who produce diplophonia. A-1: HSV image from human vocal cord. A-2: 2D DKG image from human vocal cord. A-3: DKG image from human vocal cord. B-1: HSV image from VS. B-2: 2D DKG image from VS. B-3: DKG image from VS. A-2 and A-3 noted that false vocal cord contacted regularly once every two true vocal cord contact. B-2 and B-3 showed well clearly three cycles per metacycle (triplophonia). (C) revealed peak of waveform with quasi-periodic perturbation correspond to (B-2) and (B-3). (D) presented three peak per metacycle such as (B-2) and (B-3). In normophonic male who could produce diplophonia, image of DKG from human vocal cord was very difficult to interpret because anterior false vocal cord was overlapped the true vocal fold during diplophonic phoniation (A-2 and A-3). In contrast, image of DKG from VS revealed three cycles per metacycle clearly. HSV, high-speed videocamera; 2D DKG, two-dimensional digital kymography; DKG, digital kymogram; VS, vibration simulator.

Table 1. Sensitivity, specificity, accuracy, positive likelihood ratio (LR+), and negative likelihood ratio (LR-) for auditory perceptual judgement, acoustic analysis, and digital kymography using pathologic voice samples

	TP	FP	FN	TN	Sensitivity	Specificity	Accuracy	LR+	LR-
Auditory perception	28	4	1	37	0.9655	0.9024	0.9286	9.8966	0.0382
Acoustic analysis	27	2	2	39	0.9310	0.9512	0.9428	19.0862	0.0725
Digital kymography	28	1	1	40	0.9655	0.9756	0.9714	39.5862	0.0353

TP, true positive; FP, false positive; FN, false negative; TN, true negative.

Table 2. Inter- and intra-rater reliability for auditory perceptual judgement, acoustic analysis, and digital kymography using pathologic voice samples

	Inter-rater reliability		Intra-rater reliability	
	ICC	95% CI	ICC	95% CI
Auditory perception	0.760	0.697–0.811	0.818	0.737–0.879
Acoustic analysis	0.767	0.705–0.815	0.931	0.900–0.954
Digital kymography	0.899	0.872–0.920	0.979	0.970–0.986
Total	0.809	0.782–0.833	0.967	0.954–0.977

ICC, intraclass correlation coefficient; CI, confidence interval.

0.0382, respectively (Table 1). ICC of inter- and intra-rater reliability were 0.760, 0.818, respectively (Table 2).

Visual perceptual judgement for presence of quasi-periodic perturbation in voice signal

As a result of differentiating diplophonia using visual perceptual judgement, it showed that sensitivity, specificity, accuracy, LR+, and LR- were 0.9310, 0.9512, 0.9428, 19.0862, 0.0725, respectively (Table 1). ICC of inter- and intra-rater reliability were 0.767, 0.931, respectively (Table 2). As shown in Fig. 3, we could confirm that various quasi-periodic perturbation were repeated metacycle in diplophonia.

Visual perceptual judgement for presence of quasi-periodic variation in DKG and 2D DKG

As a result of DKG and 2D DKG after input voice sample into VS, it showed that sensitivity, specificity, accuracy, LR+, and LR- were 0.9655, 0.9756, 0.9714, 39.5862, 0.0353, respectively (Table 1). ICC of inter- and intra-rater reliability were 0.899, 0.979, respectively (Table 2). As shown in Fig. 4, we could confirm that presence of subcycles and quasi-periodic variation with various metacycle length in diplophonia.

Comparison between the pattern of images in DKG and 2D DKG using HSV playbacks

Frame duration (s) was determined as Pn/Tfps. At 1350 frames/s (Tfps), one pixel line on the 240×320 display represented 0.7407 ms, so a 320-pixel frame (Pn) covered 237 ms of vocal-cord movement. The anterior and posterior movements of the VS were identical; consequently, sequential anterior-to-posterior scanning in 2D DKG produced a video with the same time domain as DKG (Fig. 4). The time represented was 118.5 ms with 2 pixel lines, 79 ms with 3, 59.4 ms with 4, and 47.4 ms with 5. For differentiating diplophonia, 2D DKG was useful in 26 of 29 samples (89.66%), and intra-rater reliability showed a high level of agreement (ICC=0.95).

Discussion

Diplophonia refers to the production of two pitches during voicing.[15] Because vocal-cord vibration cannot be readily distinguished by direct endoscopic observation alone, auditory feedback must also be considered. Diplophonia can be observed when one vocal cord differs in mass or tension, as in vocal polyps, nodules, scars, or paralysis. A related example is the Mongolian traditional throat-singing form called

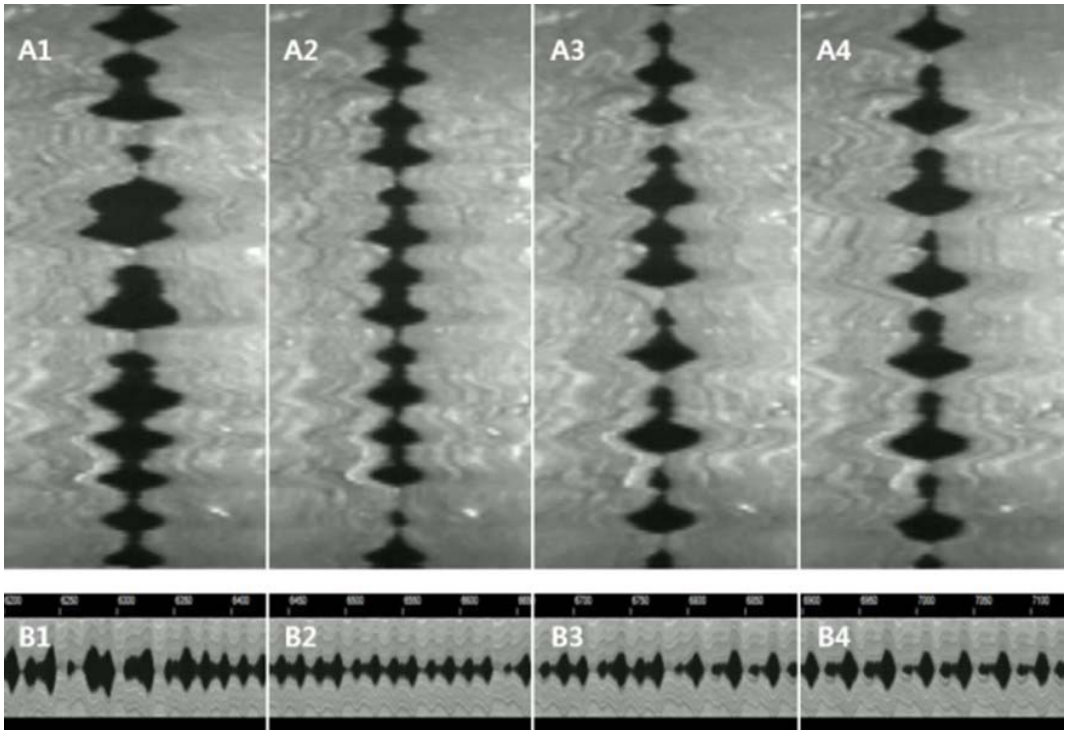

Fig. 4. Comparison of 2D DKG (A) with DKG (B) in diplophonic voice (55-year-old male, vocal cord palsy). (A) represented sequential images of 2D DKG, (B) showed serial images of DKG. Both (A1) to (B1), (A2) to (B2), (A3) to (B3), and (A4) to (B4) have same time domain. (A4) and (B4) reveal images of diplophonia (biphonia pattern). 2D DKG is much easier to evaluate because DKG is spatial image and 2D DKG is temporal image. 2D DKG, two-dimensional digital kymography; DKG, digital kymogram.

Khöömei,[16] which involves simultaneous vibration of the true and false vocal cords. In our normophonic case capable of diplophonic phonation, vibration involved the anterior part of the false vocal cord together with the true vocal cord (Fig. 3).

Diplophonia can be diagnosed using the auditory perceptual assessment,[1,17,18] acoustic analysis of voice signals,[15,17,19] EGG,[1,20] HSV,[21,22] and DKG.[18] The characteristics of diplophonia include quasi-periodic patterns in acoustic analysis of voice signals, EGG, DKG, as well as subharmonics[23,24] in sound spectrogram.

According to Titze's[25] classification, voice signals can be divided into three types depend on spectra. Type I consists of a single series of harmonics, type II consists of more than one series of harmonics or partials, and type III is whether the spectra are continuous. Of these, diplophonia corresponds to type II, whereas non-periodic voice corresponds to type III.[20]

As a result of comparison between vibration of human vocal cords and VS, vibratory pattern of VS was similar to human vocal cords in both DKG and 2D DKG (Figs. 2 and 3). These findings indicate that vibration analysis using the VS can be used as a non-invasive alternative for evaluating human vocal fold vibration.

We designed the VS system for evaluation of vibratory patterns and discriminate the diplophonic voice from pathologic voice samples using auditory perceptual judgement, acoustic analysis, DKG, and 2D DKG.

Although auditory-perceptual judgement is relatively easy to perform without specialized equipment and is widely used in clinical settings to evaluate diplophonia, its diagnostic accuracy may be limited because it relies heavily on the examiner's experience. In our study, auditory-perceptual judgement showed an accuracy of 92.86% and a LR+ of 9.8966, indicating that diplophonia was approximately 9.9 times more likely to be identified than in its absence. In addition, intra-rater reliability was the lowest among the three evaluation methods examined in this study.

The presence of quasi-periodic perturbation in acoustic waveform was widely used for the diagnosis of diplophonia.[15,22]

In our study, acoustic analysis showed an accuracy of 94.28% and an LR+ of 19.0862, indicating approximately 19 times greater discrimination of diplophonia than its absence. Although acoustic analysis was useful for discriminating diplophonia, diplophonic segments could frequently be over-

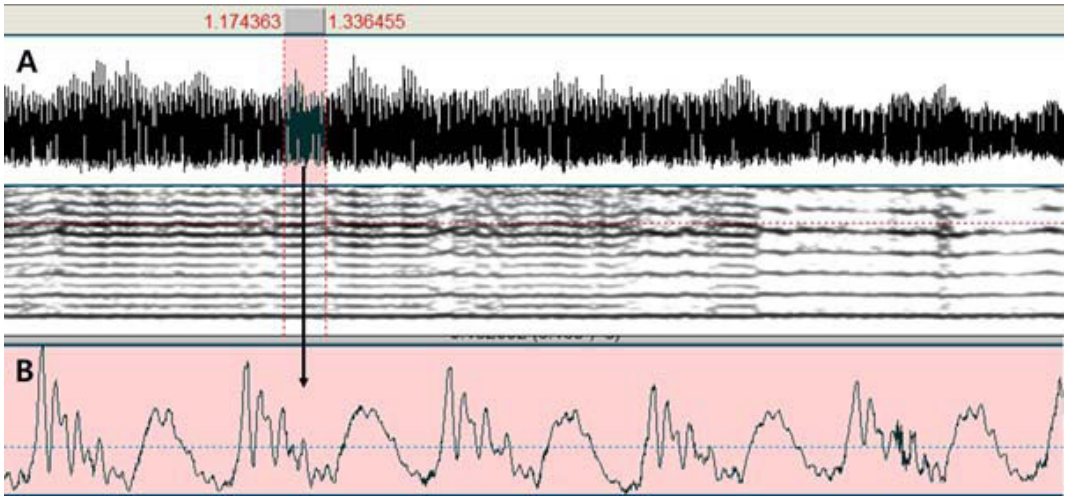

Fig. 5. Quasi-periodic perturbation in unilateral vocal cord palsy (45-year-old female, vocal cord palsy). A: Original sound waveform. B: Expanded sound waveform.

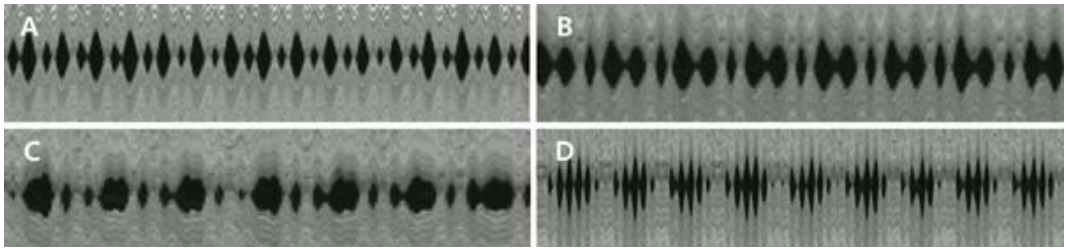

Fig. 6. Type of diplophonia according to peak in digital kymogram using vibration simulator. (A) biplophonia, (B) triplophonia, (C) quadruplophonia, and (D) multiplophonia showed various pattern of metacycle.

looked because the analysis process was cumbersome and required a high degree of concentration when raters used expanded waveforms for differentiation (Fig. 5).

Pulse counts within a metacycle provide the basis for the four types of diplophonia described by Aichinger[4] and Titze.[23] Biplophonia (biphonia) contains two cycles per metacycle, triplophonia (triphonia) contains three, quadruplophonia contains four, and multiplophonia (multiphonia) contains more than four. These waveforms can be described in terms of subcycles and metacycles, with metacycles appearing as temporal fluctuations in dominant pulse amplitudes. Applying this framework, we observed different metacycle lengths among the diplophonia samples (Fig. 6),[4] and the patterns resembled the quasi-periodic waveforms reported in GAW[26] and glottal width waveform studies.[1,22]

DKG achieved an accuracy of 97.14% and an LR+ of 39.5862, corresponding to approximately 39 times higher discrimination of diplophonia than its absence. DKG using the VS demonstrated the highest accuracy and the highest intra- and inter-rater reliability among the three evaluation methods (Tables 1 and 2). A definitive diagnosis could be made by identifying the vibratory pattern of a diplophonic segment using HSV imaging or DKG. HSV analysis is time-consuming because of its long playback time[27] and depends on visual memory for accurate assessment. Similarly, DKG analysis requires sustained concentration to locate the relevant segment.

With the VS, 2D DKG enabled real-time review at both the video and individual-frame levels. Within the framework used in this study, DKG provides spatial information about vocal-cord vibration, whereas 2D DKG provides temporal information. This allowed transient vibratory changes to be identified more intuitively, making 2D DKG relatively easier to evaluate than DKG for differentiating diplophonia. With the two-pixel-line setting, each 2D DKG frame represented 118.5 ms. Nevertheless, DKG may be more useful when a diplophonic pattern lasts approximately 40 ms or when a single 2D DKG frame cannot display more than three cycles.

Three practical limitations of conventional HSV-based DKG are system cost, the management and processing of large data files, and memory capacity.[28] The multi-functional examination system used in this study enabled simultaneous real-time analysis using DKG and 2D DKG. It encoded a 10-s HSV recording in 20 s, allowing HSV analysis to be completed more rapidly than with previous HSV systems. Therefore, the system may help overcome some of the limitations of conventional HSV.[7]

In conclusion, during pathologic voice evaluation, the silicon simulator demonstrated a vibratory pattern similar to that of the human vocal cord and was particularly useful for differentiating diplophonia. The multi-functional system incorporating HSV, DKG, and 2D DKG provided a convenient and effective means of evaluating vibratory patterns. The two kymographic methods differed in practical utility: 2D DKG was relatively easier to use for assessing pathologic voices, whereas DKG was more effective for analyzing diplophonic voices containing a long metacycle component. We expect the VS to be useful in telemedicine, as it may enable vocal cords vibration to be represented using voice alone. Future studies should investigate how consistency of silicon-block and sound intensity affect vibratory amplitude of the simulator.

Supplementary Video Legend

Video 1. Images of vocal cord vibration in normophonic male who produce diplophonia (M65). HSV in left upper; 2D DKG in right upper; DKG in bottom.

Video 2. HSV images using vibration simulator in diplophonic case (M/60, unilateral vocal cord palsy).

Supplementary Materials

The Supplement is available with this article at https://doi.org/10.3342/kjorl-hns.2026.00661.

Acknowledgments

This work was supported by a 2-year Research Grant of Pusan National University.

Author Contribution

Conceptualization: Jin Choon Lee, Soo-Geun Wang, Jung Hoon Ro. Data curation: all authors. Formal analysis: all authors. Funding acquisition: Jung Hoon Ro. Investigation: In-Ho Bae, Jaewon Kim, Soon-Bok Kwon. Methodology: Eui-Suk Sung, Minhyung Lee, Sung-Chan Shin, Yong-Il Cheon, Ha-Nee Kwon. Project administration: Jung Hoon Ro, Soo-Geun Wang. Resources: Soo-Geun Wang. Software: Jung Hoon Ro, Soo-Geun Wang. Supervision: Jung Hoon Ro, Soo-Geun Wang. Validation: Jung Hoon Ro, Soo-Geun Wang. Visualization: Jung Hoon Ro, Soo-Geun Wang. Writing—original draft: Jin Choon Lee. Writing—review & editing: Soo-Geun Wang, Jung Hoon Ro, Jin Choon Lee.

ORCIDs

Jin Choon Lee	https://orcid.org/0000-0002-4056-8763
Soo-Geun Wang	https://orcid.org/0000-0002-8059-0076
In-Ho Bae	https://orcid.org/0000-0003-4432-5192
Jaewon Kim	https://orcid.org/0000-0003-2882-7803
Eui-Suk Sung	https://orcid.org/0000-0001-8752-3426
Minhyung Lee	https://orcid.org/0000-0002-4038-1667
Sung-Chan Shin	https://orcid.org/0000-0003-2329-0648
Yong-Il Cheon	https://orcid.org/0000-0003-0288-0542
Ha-Nee Kwon	https://orcid.org/0000-0002-6965-9589
Soon-Bok Kwon	https://orcid.org/0000-0002-9424-0077
Jung Hoon Ro	https://orcid.org/0000-0002-5203-5956

REFERENCES

1) Hirose H, Kiritani S, Imagawa H. Neurogenic diplophonia: a high-speed digital image analysis. Asia Pac J Speech Lang Hear 2002; 7(2):71-8.
2) Gerratt BR, Hanson DG, Berke GS, Precoda K. Photoglottography: a clinical synopsis. J Voice 1991;5(2):98-105.
3) Wang SG, Park HJ, Lee BJ, Lee SM, Ko B, Lee SM, et al. A new videokymography system for evaluation of the vibration pattern of entire vocal folds. Auris Nasus Larynx 2016;43(3):315-21.
4) Aichinger P. Diplophonic voice–definitions, models, and detection [dissertation]. Graz: Graz University of Technology;2015.
5) Larsson H, Hertegård S, Lindestad PA, Hammarberg B. Vocal fold vibrations: high-speed imaging, kymography, and acoustic analysis: a preliminary report. Laryngoscope 2000;110(12):2117-22.
6) Tigges M, Wittenberg T, Mergell P, Eysholdt U. Imaging of vocal fold vibration by digital multi-plane kymography. Comput Med Imaging Graph 1999;23(6):323-30.
7) Kang DH, Wang SG, Park HJ, Lee JC, Jeon GR, Choi IS, et al. Real-time simultaneous DKG and 2D DKG using high-speed digital camera. J Voice 2017;31(2):247.e1-7.
8) Misun V, Svancara P, Vasek M. Experimental analysis of the characteristics of artificial vocal folds. J Voice 2011;25(3):308-18.
9) Alipour F, Berry DA, Titze IR. A finite-element model of vocal-fold vibration. J Acoust Soc Am 2000;108(6):3003-12.
10) Ruty N, Van Hirtum A, Pelorson X, Lopez I, Hirschberg A. A mechanical experimental setup to simulate vocal folds vibrations. Preliminary results. Zas Papers in Linguistics 2005;40:161-75.
11) Zañartu M, Mongeau L, Wodicka GR. Influence of acoustic loading on an effective single mass model of the vocal folds. J Acoust Soc Am 2007;121(2):1119-29.
12) Dejonckere PH, Lebacq J. An analysis of the diplophonia phenomenon. Speech Commun 1983;2(1):47-56.
13) Boersma P. The use of Praat in corpus research [online] [cited 2024 Nov 13]. Available from: URL: http://www.fon.hum.uva.nl/paul/papers/PraatForCorpora2.pdf.
14) Hong KH, Kim HK. Diplophonia in unilateral vocal fold paralysis and intracordal cyst. Otolaryngol Head Neck Surg 1999;121(6):815-9.
15) Colton RH, Casper JK, Leonard R. Understanding voice problems: a physiological perspective for diagnosis and treatment. Baltimore: Lippincott Williams & Wilkins;2006.
16) Sakakibara KI, Imagawa H, Konishi T, Kondo K, Murano EZ, Kumada M, et al. Vocal fold and false vocal fold vibrations in throat singing and synthesis of khöömei. Proceedings of the International Computer Music Conference (ICMC 2001); 2001 Sep 17-22; Havana, Cuba. San Francisco: International Computer Music Association;2001. p.135-8.
17) Kiritani S, Imagawa H, Miyaji M, Kumada M, Niimi S. Quasi-periodic pertubations pathologycal vocal fold vibration. Ann Bull RILP 1995;29:27-33.
18) Larsson H. Methods for measurement of vocal fold vibration and viscoelasticity [dissertation]. Stockholm: Karolinska Institutet;2009.
19) Kiritani S, Hirose H, Imagawa H. Vocal cord vibration and speech waveform in diplophonia. J Acoust Soc Am 1991;90(4):2345.
20) Behrman A, Agresti CJ, Blumstein E, Lee N. Microphone and electroglottographic data from dysphonic patients: type 1, 2 and 3 signals. J Voice 1998;12(2):249-60.
21) Bonilha HS, Deliyski DD, Whiteside JP, Gerlach TT. Vocal fold phase asymmetries in patients with voice disorders: a study across visualization techniques. Am J Speech Lang Pathol 2012;21(1):3-15.
22) Kiritani S, Hirose H, Imagawa H. High-speed digital image analysis of vocal cord vibration in diplophonia. Speech Commun 1993;13 (1-2):23-32.
23) Titze IR. Workshop on acoustic voice analysis: summary statement. Iowa City: National Center for Voice and Speech;1995.
24) Cavalli L, Hirson A. Diplophonia reappraised. J Voice 1999;13(4): 542-56.
25) Titze IR. Principles of voice production. Iowa City: National Center for Voice and Speech;2000.
26) Yan Y, Chen X, Bless D. Automatic tracing of vocal-fold motion from high-speed digital images. IEEE Trans Biomed Eng 2006; 53(7):1394-400.
27) Park HJ, Cha W, Kim GH, Jeon GR, Lee BJ, Shin BJ, et al. Imaging and analysis of human vocal fold vibration using two-dimensional (2D) scanning videokymography. J Voice 2016;30(3):345-53.
28) Mehta DD, Hillman RE. Current role of stroboscopy in laryngeal imaging. Curr Opin Otolaryngol Head Neck Surg 2012;20(6):429-36.